

Acute Effects of the Iranian Snake (*Naja Naja Oxiana*) Venom on Heart

S.A. Angaji^{a,*}, A. Houshmandi^a and A Zare Mirakabadi^b

^aDepartment of Cell and Molecular Biology, Faculty of Biological Sciences, Kharazmi University, Tehran, Iran

^bDepartment of Antivenin and Venomous Animals, Razi Vaccine and Serum Research Institute, Karaj, Iran

(Received 8 July 2016, Accepted 20 August 2016)

ABSTRACT

The myocardial effect of snake venoms is considered as one of the most common pathogenesis in many cases of snake envenomation. This study was undertaken to investigate the effects of the Iranian cobra (*Naja naja oxiana*) venom on cardiac function in experimental animals. The blood samples from all the rabbits were collected before venom injection, and then 140 $\mu\text{g kg}^{-1}$ venom of snake (*Naja naja oxiana*) was injected intramuscularly to the rabbits. Following venom injection the blood was collected again at 1, 3 and 24 h. Electrocardiogram (ECG) was recorded during the experiment. The levels of serum enzymes lactate dehydrogenase (LDH), creatine kinase-MB (CK-MB) and creatine phosphokinase (CPK) were determined. Statistical analyses were carried out by SPSS version 21 software. CPK enzyme showed a significant increase at 1 and 3 h after venom injection. The level of CK-MB also rose significantly after 1 h following venom injection. However, even at 24 h the level of CPK was not changed significantly, and the rise in CK-MB at 3 and 24 h following venom injection was not significant statistically. Although there was a rise in LDH level following venom injection but it was not significant. The ECG also confirmed changes in heart rhythmic and showed bradycardia and T tall. Based on the results obtained in the present study, it seems that the *Naja naja oxiana* venom has acute effect on cardiac system during the first few hours of snake bite.

Keywords: Cobra venom, Heart, *Naja naja oxiana*

INTRODUCTION

Snake bites cause high mortality rates all over the world [1]. The World Health Organization (WHO) estimates that more than 2,500,000 venomous snake bites per year can be the cause of 125,000 deaths worldwide, 100,000 of which are in Asia and approximately 20,000 in Africa [2].

The myocardial effect of snake venoms is considered as one of the most common pathogenesis in many cases of snake envenomation [3]. The *Naja naja oxiana* is a one of the most dangerous snakes belonging to elapidea family, an abundant snake in Northeast of Iran. Two main toxins as well as a number of minor components and three basic polypeptides similar to cardiotoxins (CTXs) and cytotoxins were isolated from *NNO* crude venom [4]. There are few case reports of acute myocardial infarction (MI) following snake bite [5]. Some of the symptoms and signs of myocardial effects in snakebite include bradycardia,

tachycardia, hypertension, hypotension and electrocardiographic findings [6]. Among the important complications caused by snake bite are injuries to vital organs such as the kidneys, heart, liver and lungs [7,8]. Lactate dehydrogenase (LDH), creatine kinase-MB (CK-MB) and creatine phosphokinase (CPK) are considered as markers of heart failure [9]. So far one report is available to show the effect of the Iranian Cobra (*Naja Naja Oxiana*) venom on cardiac system. Hence this study was undertaken to evaluate the effect of this snake venom on cardiac system.

MATERIALS AND METHODS

Venom Source

Cobra snake (*Naja naja oxiana*) venom was obtained from the Venomous Animal and Antivenom Production Department, Razi Vaccine and Serum Research Institute, Iran.

*Corresponding author. E-mail: angaji@khu.ac.ir

EXPERIMENTAL DESIGN

Seven male *Dutch* rabbits were selected with an average weight of 1.5 ± 0.3 kg. Rabbits were kept in the animal house for 3 days prior to the experiments. The environment was climate controlled at 18-22 °C with food and water. The animals used in the experiment showed no sign of ill health. The animals were anaesthetized by ketamine 2% and xylazine 10% in a ratio of 1:1. The ECG with lead II was recorded during the experiment. Blood samples were collected from the ear vein of animals for serum analyses before and after subcutaneous venom ($140 \mu\text{g kg}^{-1}$) injection at 1, 3 and 24 h. The sera were separated and used for determination of CPK, CK-MB and LDH levels using kits from Pars Azmoon Company (Iran).

Statistical Analyses of Data

One-way ANOVA was used to compare the results between the groups and Tukey test was carried out to compare the sets of means in different groups using SPSS, version 21. The level of significance was set at less than 0.05.

RESULTS

Clinical Observation

The first signs and symptoms of envenomation appeared 15 minutes after venom injection. The clinical effects including paralysis in hands and legs, droop and phlegm, abnormal respiration, loose pupil, humility eyelids, and muscle contraction were observed following venom injection.

Biochemical Parameters

As shown in Fig. 1, the level of CPK in envenomed rabbits sera was elevated 257% 1 h after venom injection and the rise was statistically significant ($p = 0.003$). The means of SEM were 386 ± 41 U/L for before injection and 1382 ± 139 U/L for one hour after injection. The rise was 255% at 3 h and statistically significant ($p = 0.004$) (1375 ± 65 U/L). However, at 24 h the level of CPK was still higher than normal by 99% which was non-significant when compared to the level before venom injection (839 ± 61 U/L).

Figure 2 displays the levels of CK-MB isoenzyme. This parameter after 1 h of venom injection was increased by 85% compared to its levels before venom injection. The means of SEM were 228 ± 15 U/L for before injection and 422 ± 38 U/L for one hour following injection. This rise was significant at $p = 0.011$. However, after 3 h it showed a 55% increase which was not significant (345 ± 19 U/L). When the level of CK-MB was determined at 24 h following venom injection, it was only 16% higher than normal, and the difference was not statistically significant (266 ± 25 U/L).

As shown in Fig. 3, the level of LDH increased by 153% at 1 h. The means of SEM were 225 ± 59 U/L for before injection and 452 ± 109 U/L for one hour after injection, which was not statistically significant. This rise continued even at 3 h (533 ± 115 U/L) but decreased after 24 h following venom injection (414 ± 81 U/L).

Electrocardiogram

As shown in Fig. 4 within 15 min following venom injection, bradycardia with T tall started and continued to 1 and 3 h. However, the ECG returned to normal state after 24 h.

DISCUSSIONS

The *Naja naja oxiana* is a one of the most dangerous snakes belonging to elapidea family and is an abundant snake in Northeast Iran. Two main toxins as well as a number of minor components and three basic polypeptides similar to CTXs and cytotoxins were isolated from *NNO* crude venom [4,10]. Myocardial infarction as a complication during snake bite by snakes belonging to Elapidae family has been observed in some victims [11]. In the present study, the levels of biochemical parameters, related to cardiac complications, such as CPK and CK-MB showed a significant increase. This finding is similar to those of Shaban and colleagues in 2003 on *Naja haje* venom in rats [12]. The cardiotoxic effect (systolic cardiac arrest) of crude cobra venom as well as venom derived fractions in frogs and toads were reported by Wong and colleagues in 2010 [13]. Reid reported significant ECG changes (ST segment depression and T wave changes) in a patient after a cobra bite [14]. Agarwal and colleagues reported

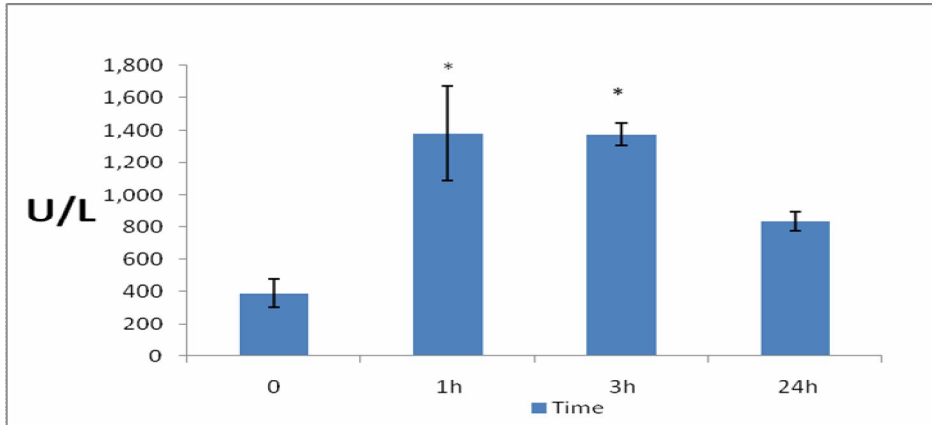


Fig. 1. The mean \pm SEM of serum CPK in rabbit. *Indicates significance at $p < 0.05$.

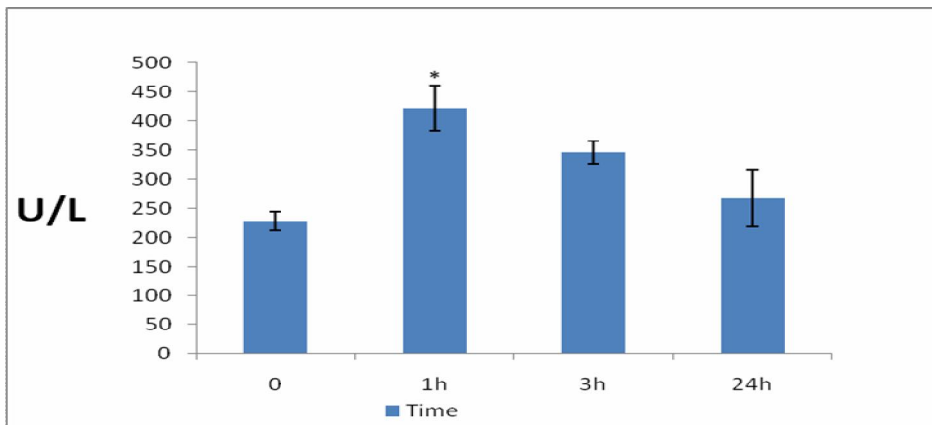


Fig. 2. The mean \pm SEM of serum CK-MB. *: Indicates significance at $p < 0.05$.

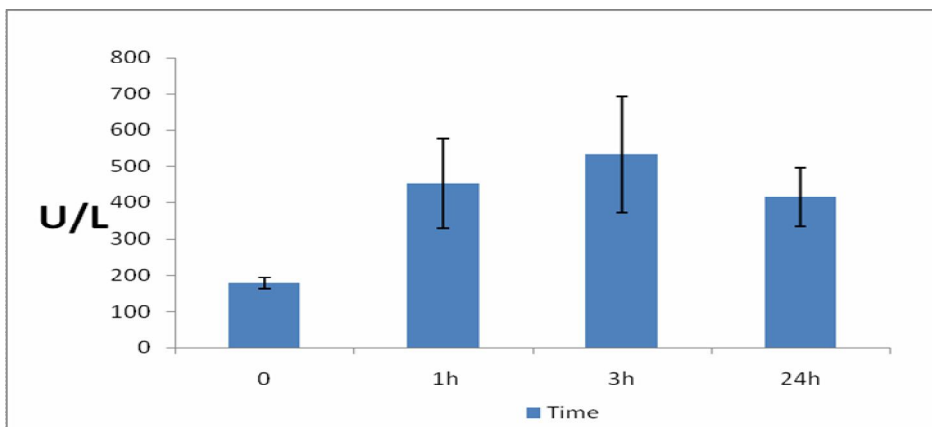


Fig. 3. The mean \pm SEM of serum LDH in rabbit. *Indicates significance at $p < 0.05$.

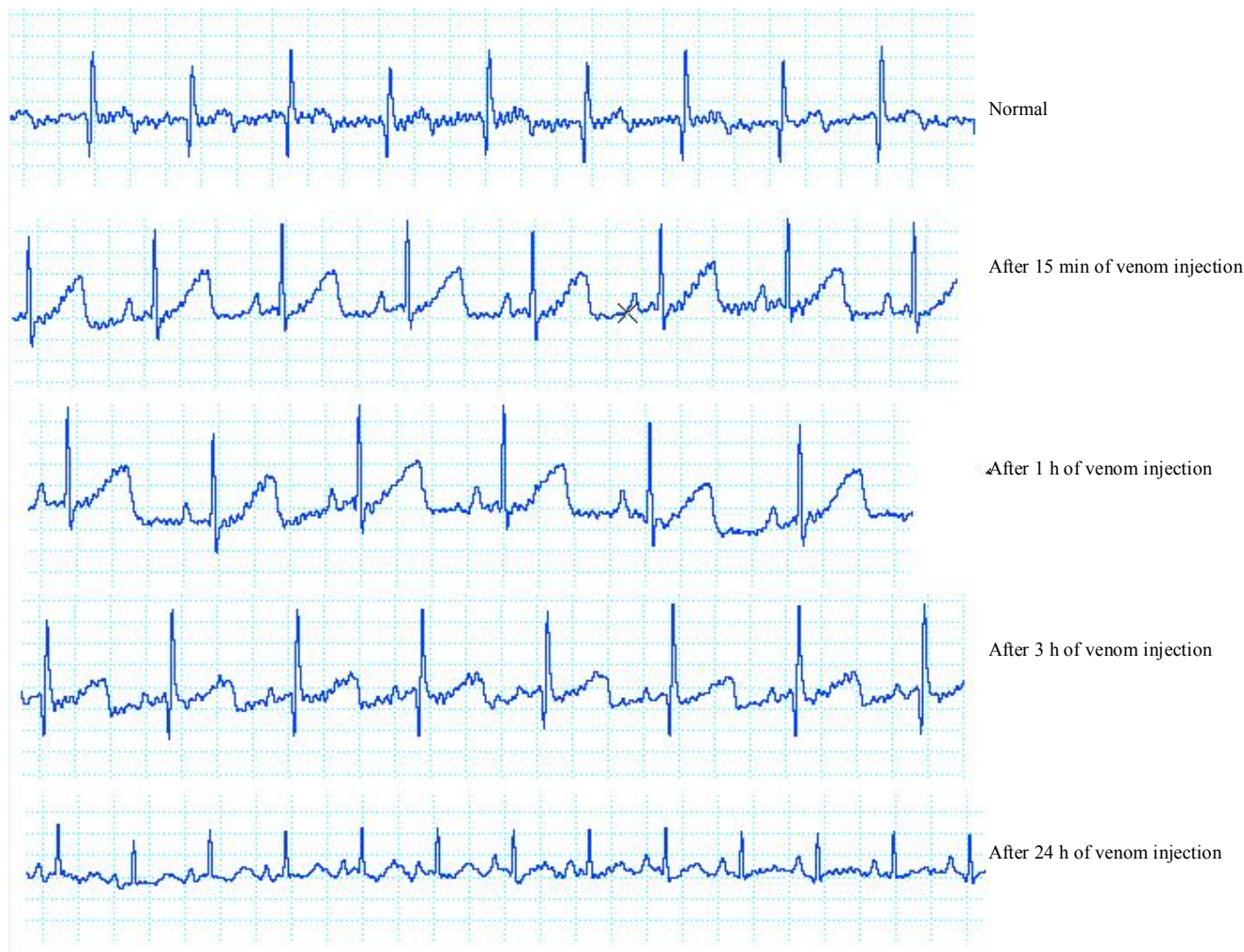

Fig. 4. The ECG records of rabbits at various time intervals following venom injection.

cardiogenic edema by injection of *Bungarus coeruleus*. They showed histopathological changes including multifocal areas of necrosis and hemorrhage in heart, and heart fibers [15]. Snake venom CTXs are small molecules with an average weight of 6.5-7.0 kDa. They exhibited a wide variety of biological activities, which include contraction of cardiac muscles, lysis of erythrocytes, and selective killing of certain types of tumor cells [16]. It was reported that CTXs from cobra snake venom can cause various cardiac manifestations in patients bitten by such snakes [17,18]. There are some concepts put forward to explain the ECG changes seen in snakebite patients, but

none of these have been universally accepted [19]. However, some mechanisms put forward by researchers are as follows: Direct action of CTXs causing myocardial damage and suppression of myocardial function, myotoxins causing rhabdomyolysis and myocardial damage, coronary vasospasm leading to myocardial ischaemia, coronary artery thrombosis, especially in patients with a consumption coagulopathy, leading to coronary occlusion, haemorrhage in the venom causing myocardial haemorrhage, electrolytes abnormalities causing electrical changes, severe hypotension and/or respiratory failure causing hypoxia, leading to coronary insufficiency and finally cardiac

autonomic nervous supply disturbance [18]. These snakes also have neurotoxins that can cause morphological changes, enzyme changes and structural abnormalities [20].

On the other hand, although the level of LDH rose following venom injection but this rise was not significant statistically. This could be due to existence of different LDH isoenzymes. Bradycardia caused by the ECG findings may be due to general paralysis of the animal that can create impaired breathing, hypoxia and bradycardia. The increase in T wave height represents myocardial damage and subsequently released potassium from myocardial cells. Other complications of hyperkalemia can be anomalies in the rate of body electrolytes and consequently myocardial damage. Weakness, paraplegia and difficulty in breathing are also parts of hyperkalemia symptoms and can be the cause of hypoxia and bradycardia that have been observed in envenomed rabbits.

CONCLUSIONS

Based on the results obtained in the present study, it appears that the venom of the Iranian cobra (*Naja naja oxiana*) has acute effects on cardiac tissue during the first few hours following snake bite.

ACKNOWLEDGMENTS

This project was supported by the Department of Venomous animals and antivenom production, Razi Venomous & Serum Research Institute, Karaj, Iran.

REFERENCES

- [1] M.H. Asad, M.T. Razi T. Khan, Q.N. Saqip, G. Mortaza, M.S. Hussain M.S. Hussain, S. Karim, I. Hussain, Acta Pol. Pharm. 69 (2012) 1032.
- [2] L.S. Cruz, R. Vargas, A.A. Lopes, Ethn. Dis. 19 (2009) 42.
- [3] R. Shashidharamurthy, Y.H. Mahadeswaraswamy, L. Ragupathi, B.S. Vishwanath, K. Kemparaju, Exp. Toxicol. Pathol. 62 (2010) 587.
- [4] A. Akbari, H. Rabiei, A. Hedayat, N. Mohammadpour, H. Zolfagharian, Sh. Teimorzadeh, Arch. Razi Institute 65 (2010) 33.
- [5] M. Maheshwari, S.R. Mittal, JAPI. 52 (2002) 63.
- [6] S. Jensen, Clinical Management of Snake bite in Papua New Guinea 4 (2005) 1.
- [7] A. Tohamy, A. Mohamed, A. Abdel Moneim, M. Diab, J. King Saud University Sci. (2014) 1-8.
- [8] C.D. Cher, A. Armugam, Y.Z. Zhu, K. Jeyaseelan, Molecular Basis of Cardiotoxicity upon Cobra Envenomation 62 (2005) 105.
- [9] R. Dufour, Lab. Medicine Practice Guidelines. 12 (2000) 67.
- [10] T. Matsui, Y. Fujimura, K. Titani, Biochim. Biophys. Acta 1447 (2000) 146.
- [11] L. Abdel Ghani, M.O. El-Asmer, T. Abbas Rahmy, Egyptian Journal of Natural Toxins. 7 (2010) 1.
- [12] E.A. Shaban, N. Hafez, The Egyptian Journal of Hospital Medicine. 13 (2003) 135.
- [13] O.S.K. Wong, T. Lam, H. Fung, C. Choy, Hong Kong Med. J. 16 (2010) 36.
- [14] H.A. Reid, Br. Med. J. 2 (1964) 540.
- [15] R. Agarwal, A.P. Singh, A.N. Aggarwal, Singapore Med. J. 48 (2007) 227.
- [16] G. Jayaraman, T. Kumar, C. Tsai, S. Srisailam, S. Chou, C. Ho, Protein Soc. 9 (2000) 637.
- [17] C. Chang, S. Chuang, C.Y. Lee, J.W. Wei, Br. J. Pharmac. 44 (1972) 752.
- [18] T.K.S. Kumar, G. Jayaraman, C.S. Lee, A.I. Arunkumar, T. Sivaraman, D. Samuel, C. Yu, J. Biomol. Struct. Dyn. 15 (1997) 431.
- [19] K.L. Aaron, D. Williams, S. Jensen, Clinical Management of Snakebite in Papua New Guinea. 10 (2005) 1.
- [20] V. Anbazhagan, P.S. Reddy, C. Yu, Toxin Rev. 26 (2007) 203.