Biomacromol. J., Vol.12, No.,2, July 2026.

Biomacromolecular Journal
www.bmmj.org

Anti-inflammatory/anti-amyloidogenic Effects of Crocin & Tannic Acid in Diabetes

Sara Hojat Jalali[1], Parichehreh Yaghmaei[1]*, Azadeh Ebrahim-Habibi[2,3], Parvaneh Maghami[1]

[1]Department of Biology, SR.C., Islamic Azad University, Tehran, Iran; Postal Code: 1477893855
[2]Biosensor Research Center, Endocrinology and Metabolism Molecular-Cellular Sciences Institute, Tehran University of Medical Sciences, Tehran, Iran.
[3]Endocrinology and Metabolism Research Center, Endocrinology and Metabolism Clinical Sciences Institute, Tehran University of Medical Sciences, Tehran, Iran

(Received 7 June 2026, Accepted 16 August 2026)

ABSTRACT

Insulin-derived amyloidosis (AIns) results from chronic administration of insulin in diabetes mellitus patients and is marked by amyloid fibril deposition at the injection sites. Such deposits affect glycemic control. This study aimed to evaluate the therapeutic effectiveness of crocin and tannic acid in reducing damage associated with insulin-derived amyloidosis using a diabetic Wistar rat model. Experimental groups consisted of four Wistar rats (n=4). Non-diabetic control group was maintained under standard conditions, while diabetic controls received no treatment. Sham group was injected with DMSO. To assess the effects of insulin and its amyloid form, one group was injected daily with regular insulin (EXP1), and another with insulin amyloid fibrils (EXP2). Tannic acid was co-administered with either regular insulin (EXP3) or insulin amyloid fibrils (EXP4). The effects of crocin were evaluated by administering crocin with regular insulin (EXP5) or with phosphate buffer (EXP6). Biochemical analyses included measurements of blood glucose, cholesterol, HDL, and LDL. Levels of IL-6, IL-1β, and TNF-α were quantified using ELISA, while their protein expression was assessed via Western blotting. Histopathological examinations of pancreatic and subcutaneous tissues were performed to evaluate amyloid deposition and inflammatory cell infiltration. Results showed significant reductions in TNF-α, IL-6, and IL-1β—particularly in EXP5. Histopathological findings demonstrated decreased amyloid deposition, better preservation of pancreatic islet structure, and reduced inflammatory infiltration. These findings highlight the therapeutic potential of crocin and tannic acid as natural compounds that may be used in managing insulin-derived amyloidosis.

Keywords: Amyloidosis, Crocin, Diabetes Mellitus, Insulin Resistance, IL-6, IL-1β, TNF-α.

***Corresponding author. E-mail:** yaghmaei_p@srbiau.ac.ir

INTRODUCTION

Diabetes mellitus is a metabolic disorder marked by an increased level of sugar in the blood due to a malfunction of either the secretion or action of insulin or both [1]. Diabetes is a heterogeneous syndrome associated with defined hyperglycemia and is usually divided into different types, including type 1 diabetes (T1D), type 2 diabetes (T2D), and other specific types such as, gestational diabetes [2]. Type 1 diabetes is a condition that affects about 5–10% of patients with diabetes as a result of the destruction of pancreatic β cells [1]. T2D is a nonautoimmune, and heterogeneously progressive loss in improving the adequacy of islet β cell secretion of insulin frequently associated with insulin resistance (IR) and metabolic syndrome (MS). At present, T2D comprises 96% of the patient populations and constitutes an important non-communicable, chronic disease [2]. Amyloid protein deposition in the pancreas and brain microvasculature increases health risks by reducing beta cell mass, impairing insulin secretion, and disrupts glucose metabolism, potentially worsening Alzheimer's disease pathology [3, 4]. As an example, amylin concentration increases in the central nervous system, leading to various complications including cognitive impairment and renal hypertension [5-7]. Insulin-derived amyloidosis (AIns) is a rare but serious complication due to long-term insulin therapy in patients with diabetes mellitus. It presents as localized subcutaneous amyloid deposits at insulin injection sites and usually appears as firm, palpable nodules. These amyloid masses are constituted by aggregation of insulin molecules, which, with time, misfold and arrange into insoluble fibrils. These deposits may interfere with insulin absorption and result in glycemic control that is unpredictable, and increased insulin doses to achieve target blood glucose levels [8]. A plausible way to counteract this condition is to use potential anti-amyloidogenic compounds. Tannic acid is an organic polyphenol found in various plants, including legumes, sorghum, beans, bananas, raspberries, and grapes. It possesses anti-inflammatory, antioxidant, bactericidal, antiviral, and antifungal properties. Tannic acid also inhibits amyloid formation from abeta [9, 10]. The chemical structure of tannic acid (Figure 1A) features multiple galloyl groups (Shown in blue), where the phenolic hydroxyl groups (Shown in red) serve as the primary functional sites. These groups facilitate extensive hydrogen bonding with the polypeptide backbone, effectively stabilizing the native conformation and hindering the formation of beta-sheet-rich amyloid structures.

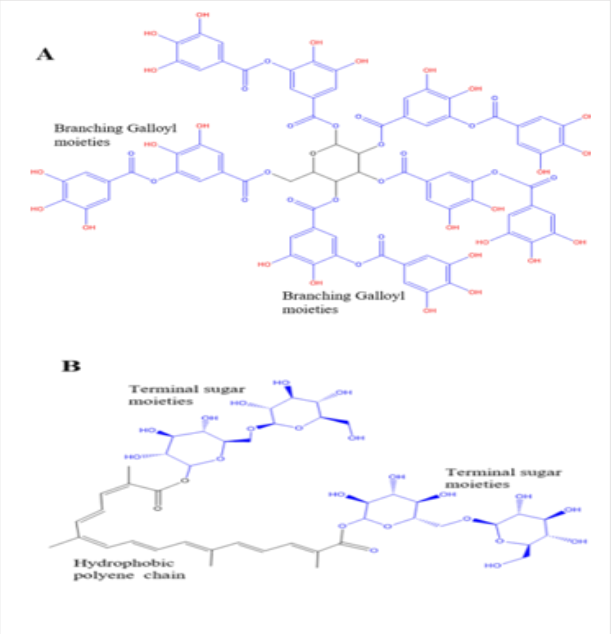

Figure 1. Chemical structure and functional groups of Tannic acid (A) and Crocin (B).

Scientists have shown that crocin, a nutraceutical carotenoid from saffron, can bring about an anti-inflammatory as well as anticancer effect [11]. In addition to its well-known anti-inflammatory and anticancer activities, Crocin has also been described to influence the formation of amyloid fibrils, which are considered the hallmark of many pathologies, such as Alzheimer's disease and insulin-induced amyloidosis. As depicted in Figure 1B, the structure of crocin comprises a hydrophobic polyene chain (highlighted in black), which is crucial for targeting the hydrophobic patches of misfolding peptides, while the terminal sugar moieties (highlighted in red) enhance its solubility and modulate the interaction kinetics through steric hindrance. Studies indicate that Crocin protects against amyloid fibril formation. More specifically, it has been described to inhibit the aggregation of the amyloid-beta (Aβ42) peptide, a critical determinant of Alzheimer's disease, by preventing fibril formation *in vitro* [12]. In addition, it was noted that Crocin inhibits urea-induced amyloid aggregation by bovine β-lactoglobulin, indicating a possible role of this compound in the diminution of amyloid-related toxicity in other systems. These observations suggest that Crocin may intervene early in protein misfolding and aggregation, indicating its therapeutic potential for amyloid-associated diseases [13].

The aim of this study was to investigate the therapeutic effect of tannic acid and crocin on insulin-induced amyloidosis, which has several clinical implications such as poor glycemic control [8]. By examining the effects of these two substances on amyloid accumulation, this research sought to gain insight into potential therapeutic interventions for this overlooked condition. In this regard, we injected these compounds with regular insulin and/or insulin fibrils in diabetic male Wistar rat model. Then, we evaluated the blood levels of glucose cholesterol, inflammatory factors and histological changes of injection site to assess the anti-amyloidosis potential of tannic acid and Crocin.

MATERIALS AND METHODS

Experimental Model

Male Wistar rats (150–200 g) were obtained from the Tehran Institute of Research for in vivo experiments. The animals were housed in a pathogen-free environment under controlled conditions: a 12-hour light-dark cycle, a standard temperature of 22 ± 2°C, and adequate ventilation. The cages were routinely sanitized, and the rats were supplied with a normal meal and fresh drinking water. Four rats were accommodated in each cage. The rats were housed at the animal facility for one week to facilitate acclimatization before the commencement of the research. Following acclimation, the rats were weighed, and those with comparable body weights were assigned to the same cage. Animal experiments were approved by the Islamic Azad University, Science and Research Branch committee (proposal of 08-02-98).

Study Design

In this study, diabetes was induced by an alloxan injection of 120 mg per kg intraperitoneally in a citrate buffer of pH 4.5 [14]. The dose was standardized according to the weight of each rat. Blood glucose levels were measured using a

glucometer about 72 hours later to ascertain the development of the disease in those animals. After confirming diabetes, the rats were divided into groups for various treatment tests as mentioned in table below (Table1). All animals were evaluated for 72 hours after alloxan injection and thereafter throughout the interventions to monitor the visual signs of acute nephrotoxicity, including weight loss, reduction in food intake, and decreased urine volume. Animals that showed any or all of the above signs were excluded from the study. Treatment dosages were based on an invitro study on insulin fibrils formation (data to be published).

Table 1. Summary of Experimental Groups and Treatment Descriptions in the Study.

Group	Description
Control Group	Non-diabetic rats with usual feeding and hydration
Diabetic Control Group (Negative Group)	Diabetic rats that received daily nourishment but no treatment
Sham Group	Diabetic rats receiving a daily injection of 0.5 mL of DMSO as a solvent control
Experimental Group I	Diabetic rats receiving daily injection of 500 µL of regular insulin solution in phosphate buffer (7.4)
Experimental Group II	Diabetic rats receiving daily injection of 500 µL of a solution containing insulin fibrils in phosphate buffer (7.4)
Experimental Group III	Diabetic rats receiving daily injection of 500 µL of regular insulin and 0.00213 mg/kg tannic acid (dissolved in DMSO) daily for 21 days
Experimental Group IV	Diabetic rats receiving daily injection of 500 µL of insulin amyloid fibrils formed in the vicinity of 0.00213 mg/kg tannic acid (originally dissolved in DMSO)
Experimental Group V	Diabetic rats receiving daily injection with 500 µL of regular insulin and 0.01221 mg/kg Crocin (dissolved in DMSO)
Experimental Group VI	Diabetic rats receiving daily injection with 500 µL of phosphate buffer (7.4) formed in the vicinity of 0.01221 mg/kg Crocin (originally dissolved in DMSO)

Measurement of biochemical parameters

Blood glucose levels were determined using a glucokinase spectrophotometric-based enzymatic kit (Delta.DP, Iran).

Cholesterol was determined using the enzymatic and colorimetric CHOD-PAP method, involving a single-point photometric analysis (Delta.DP, Iran) [15, 16]. Serum HDL concentration was measured after precipitation of lipoproteins containing apolipoprotein B100 (Delta.DP, Iran) [17]. Serum LDL concentration was also calculated indirectly by the Friedewald equation, where LDL cholesterol is estimated by subtracting the sum of HDL cholesterol and one-fifth of the triglyceride concentration (Pishtaz Teb, Iran) [18].

Measurement of inflammatory factors (IL-6, IL-1β, TNF-α)

The serum levels of interleukin-6 (IL-6), interleukin-1β (IL-1β), and tumor necrosis factor-alpha (TNF-α) were quantified using specific enzyme-linked immunosorbent assay (ELISA) kits IL-6 (CUSABIO, USA), IL-1β (P&D, USA), TNF-α (P&D, USA). Following the manufacturer's protocols (ZellBio GmbH, Germany).

Western Blot

Western blot analyses were performed as previously described with some modifications. For western blotting, tissue was lysed with Ripa buffer. The lysates were removed by centrifugation at 14,000 rpm for 20 min at 4°C. Protein concentration was determined by the Bradford Protein Quantification kit (DNAbiotech, Iran), according to manufacturer's instructions. The tissue lysates were mixed with equal volume of 2X Laemmli sample buffer. Lysates (20 µg) were then subjected to SDS-PAGE after a 5 min boiling and subsequently transferred to a 0.2 µm immune-Blot™ polyvinylidene difluoride (PVDF) membrane (Bio-Rad Laboratories, CA, USA). The membranes were then blocked with 5% BSA (Sigma Aldrich, MO, USA) in 0.1% Tween 20 for 1 h. Then, the membranes were incubated with Anti-IL-6 (Abcam, USA), Anti-TNF-α (Abcam, USA). Anti-IL1-β (Abcam, USA), and anti-β actin-loading control antibodies (Abcam, USA) for 1 h at room temperature. Subsequently, membranes were washed thrice with TBST, and incubated with goat anti-rabbit IgG H&L (HRP) (Abcam, USA) as the secondary antibody. The membranes were then incubated with enhanced chemiluminescence (ECL) for 1–2 min. Protein expression was normalized to β-actin. Densitometry of protein bands was performed using the gel analyzer Version 2010a software (NIH, USA), such that, the percentage area under the curve of each band was divided by the percentage area under the curve of its corresponding actin band, and then calculated values were compared between groups as we described previously.

Histological Studies

Tissue preparation involved skin biopsies and the excision of pancreatic tissues. Samples were fixed in formalin to preserve their structure, dehydrated through a graded alcohol series, cleared in xylene, and embedded in paraffin. After molding, they were sliced into thin sections using a microtome. These sections underwent histological examination following hematoxylin and eosin (H&E) staining. Slides were prepared and examined under light

microscopy for morphology of tissue and histopathology determined. A quantitative histological score (0: no change; 1: slight; 2: moderate; 3: severe; and 4: very severe) was performed based on inflammatory cells infiltration, fibrous tissue formation and Islets Degeneration using ImageJ.

Statistical analysis

SPSS software (Version 27) was used and one-way ANOVA, and the Tukey test were employed to analyze the data. The results were displayed as Mean ± Sem and were deemed significant at P<0.05. Excel software was used to create the graphs.

RESULTS

This study examined the effect of tannic acid and Crocin on the *in vivo* effects of insulin amyloid structures in male Wistar rats. The main objective was to assess whether these compounds can impact the effects of insulin amyloid fibrils, as the hallmark of insulin-related amyloidosis and contributes in alleviating this condition related problems.

Blood Parameters

Serum Glucose Levels

Significant variations in serum glucose levels were observed among the investigated groups. The increase was statistically significant when comparing the negative control with the control group (P<0.001). The serum glucose levels were decreased significantly in comparison with the control and the sham group (P<0.05), with experimental groups EXP1-6 (P<0.001), and the EXP2 group (P<0.01). Mean glucose levels in the experimental groups were significantly lower (P<0.05) than in the sham group. The reduction involved value changes in EXP3 and EXP5 compared to EXP1, EXP4, and EXP6 with EXP2, but these changes lacked statistical significance (Figure 2).

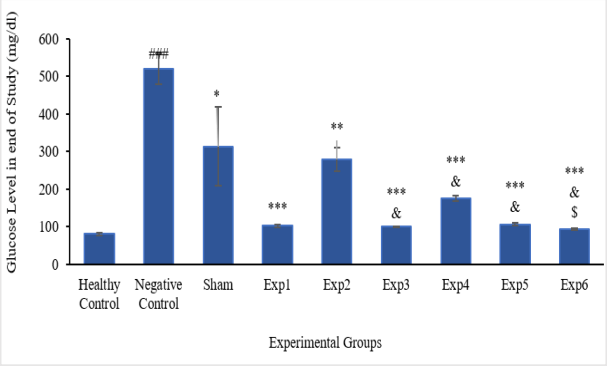

Figure 2. Serum glucose levels. The graph showed significant relationships between the negative control group, experimental groups, and the sham group. Significant relationships were also observed between experimental groups 3 to 6 and the sham group and between experimental groups 3 and 5 and experimental group 1. # indicates significant differences in the negative control group (mean ± SEM) (P < 0.05#; P < 0.01##; P < 0.001###). * Denotes significance between experimental groups and the negative control group (mean ± SEM) (P < 0.05; P < 0.01**; P < 0.001***). & represents significant differences in experimental groups 3–6 versus the sham group (mean ± SEM) (P < 0.05&; P < 0.01&&; P < 0.001&&&). + indicates significance between experimental groups 3 and 5 versus EXP1 (mean ± SEM) (P < 0.05+; P < 0.01++; P < 0.001+++). $ marks significance between experimental groups 4 and 6 versus EXP2 (mean ± SEM) (P < 0.05$; P < 0.01$$; P < 0.001$$$).

Serum Cholesterol Levels

In the groups of analysis, a substantial increase in serum cholesterol levels was observed in the negative control group compared to the control group (P<0.05). Although all experimental groups showed lower levels of serum cholesterol, this reduction was statistically significant only in EXP2 (P<0.05), EXP4 (P < 0.01), and EXP6 (P<0.05) compared to the negative control group (Figure 3).

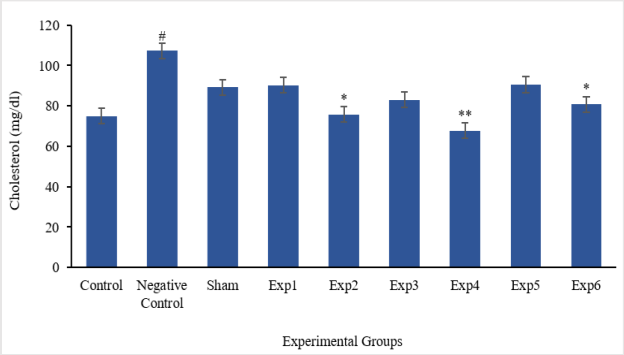

Figure 3. Serum Cholesterol levels. # indicates significance for the negative control group (P < 0.05#, P < 0.01##, P < 0.001###). * Denotes significance between experimental groups and the negative control group (P < 0.05*, P < 0.01**, P < 0.001***). & signifies significance for experimental groups 3–6 compared to the sham group (P < 0.05&, P < 0.01&&, P < 0.001&&&). + represents significance for experimental groups 3 and 5 versus EXP1 (P < 0.05+, P < 0.01++, P < 0.001+++). $ marks significance for experimental groups 4 and 6 versus EXP2 (P < 0.05 $, P < 0.01 $$, P < 0.001 $$$).

Serum LDL & HDL Levels

Serum LDL levels were significantly lower in both the experimental and sham groups when compared to the negative control group. This diminution was statistically significant in the sham and EXP3 groups (P < 0.05) and in EXP4 (P < 0.01). While LDL levels were reduced in other experimental groups, these changes were not statistically significant (Figure 4A). On the other hand, serum HDL levels showed an enhancement in both the experimental and sham groups relative to the negative control group. This increment was significant in the sham and EXP3 groups (P < 0.05), as well as in EXP1 (P < 0.001) and EXP5 (P < 0.01). However, HDL levels in EXP4 and EXP6 were significantly lower than those in EXP2, with EXP4 demonstrating a notable rise at (P < 0.01) (Figure 4B).

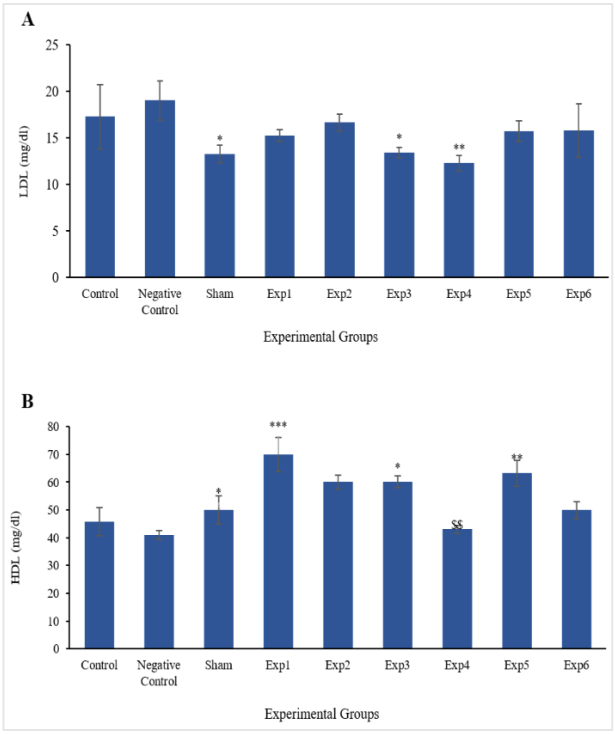

Figure 4. A) Serum LDL levels. B) Serum HDL levels. # indicates the relationship between the negative control group and the control group (P < 0.05#, P < 0.01##, P < 0.001###). * Denotes significance between the experimental groups and the negative control group (P < 0.05*, P < 0.01**, P < 0.001***). & signifies the relationship of experimental groups 3–6 with the sham group (P < 0.05&, P< 0.01 &&, P< 0.001 &&&). + indicates significance between experimental groups 3 and 5 with experimental group 1 (P < 0.05+, P < 0.01++, P < 0.001+++). $ marks the relationship of experimental groups 4 and 6 with experimental group 2 (P < 0.05$, P < 0.01 $$, P< 0.001 $$$).

Analysis of Serum Levels of TNF-α, IL-6, and IL-1ß in the Studied Animal Groups

The interventions significantly altered serum levels of inflammatory cytokines, including TNF-α, IL-6, and IL-1ß in the experimental groups. The level of TNF-α was significantly higher in the negative control group than in the control group (p < 0.001). Both sham and experimental groups showed significantly lower TNF-α levels than the negative control group (p < 0.001). Among the experimental groups,

EXP3, EXP4, EXP5, and EXP6 showed significantly lower TNF-α levels compared to the sham group ($p < 0.001$). EXP4 and EXP6 exhibited even lower TNF-α levels than EXP2 ($p < 0.001$) (Figure 5A). IL-6 levels were significantly higher in the negative control group compared to the control group ($p < 0.001$). Both sham and experimental groups showed lower levels compared to the negative control, with significantly lower levels in EXP1, EXP3, EXP4, EXP5, and EXP6 ($p < 0.001$), while EXP2 demonstrated a smaller but still significant reduction. For the sham group, relative levels of IL-6 were lower in EXP3, EXP4, EXP5, and EXP6, with significantly lower levels in EXP3 ($p < 0.05$), EXP5, and EXP6 ($p < 0.01$). IL-6 levels in EXP4 and EXP6 were significantly lower than in EXP2, particularly in EXP6 ($p < 0.001$) (Figure 5B). The negative control group showed significantly higher serum IL-1ß levels compared to the control group ($p < 0.001$). All sham and experimental groups showed lower IL-1ß values compared to the negative control, with significantly lower levels in EXP1, EXP4, and EXP6 ($p < 0.01$), as well as in EXP3 and EXP5 ($p < 0.001$). Comparison with the sham group showed a significantly lower value for IL-1ß in EXP3 (Figure 5C).

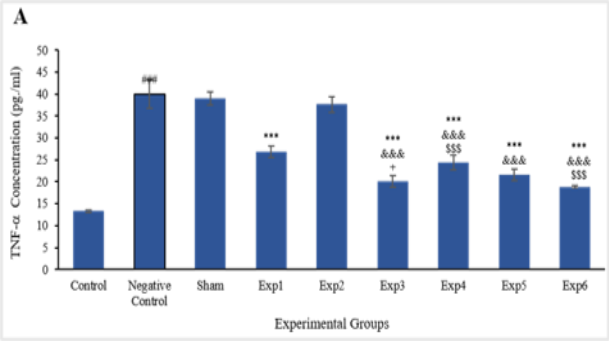

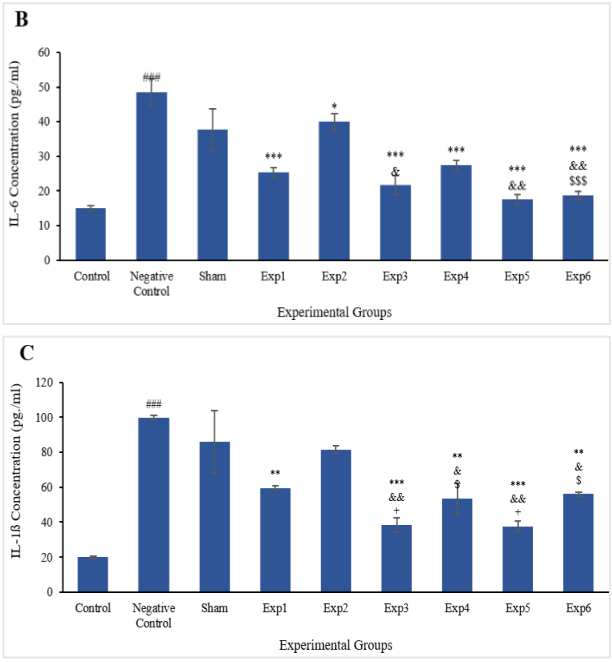

Figure 5. A) TNF-α, B) IL-6 and C) IL-1ß serum levels. Statistical significance is denoted by the following symbols: the relationship between the negative control group and the control group is indicated by # (mean ± SEM; $p < 0.05$#, $p < 0.01$##, $p < 0.001$###); the relationship between the experimental groups and the negative control group is indicated by * (mean ± SEM; $p < 0.05$*, $p < 0.01$**, $p < 0.001$***); the relationship between experimental groups 3–6 and the sham group is indicated by & (mean ± SEM; $p < 0.05$&, $p < 0.01$&&, $p < 0.001$&&&); the relationship between experimental groups 3 and 5 and experimental group 1 is indicated by + (mean ± SEM; $p < 0.05$+, $p < 0.01$++, $p < 0.001$+++); and the relationship between experimental groups 4 and 6 and experimental group 2 is indicated by $ (mean ± SEM; $p < 0.05$$, $p < 0.01$$$, $p < 0.001$$$$).

Western Blot Analysis

The compounds used in this experiment (0.01221 mg/kg Crocin and 0.00213 mg/kg tannic acid) were able to lower the expression of inflammatory markers (IL-6, IL-1ß, and TNF-α) in two settings, one with regular insulin and one with insulin amyloid fibrils, according to the results obtained. A quantitative analysis with Western blot (using a gel analyzer) was performed to further observe the compounds

effects at protein level. The results show that TNF-α, IL-6, and IL-1ß levels were significantly higher in the negative control group compared to the corresponding control group ($p < 0.001$). However, all experimental groups exhibited a significant reduction of these protein bands compared to the negative control group. Significant reductions were observed for TNF-α in EXP1, EXP3, EXP5, and EXP6 ($p < 0.001$), EXP2 ($p < 0.05$), and EXP4 ($p < 0.01$); for IL-6 in EXP1, EXP3, EXP4, EXP5, EXP6, and EXP2 ($p < 0.001$); and for IL-1ß in EXP1, EXP3, EXP4, and EXP6 ($p < 0.001$). Additionally, the TNF-α, IL-6, and IL-1ß levels in experimental groups EXP3–EXP6 were significantly reduced compared to the sham group ($p < 0.01$ for TNF-α, $p < 0.001$ for IL-6 and IL-1ß). No significant reductions in the TNF-α or IL-6 bands were observed in EXP3 and EXP5 compared to EXP1. A significant downregulation in IL-1ß levels was observed in EXP3 compared to EXP1 ($p < 0.05$). In addition, significantly lower reductions were observed in the bands for IL-6 and IL-1ß in EXP4 and EXP6 compared to EXP2 ($p < 0.001$) and for IL-6, $p < 0.05$ for IL-1ß in EXP4, $p < 0.01$ in EXP6). Beta-actin protein was used as a standard (Figure 6).

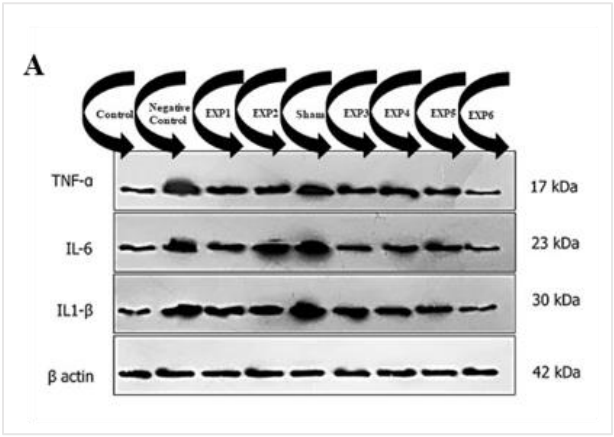

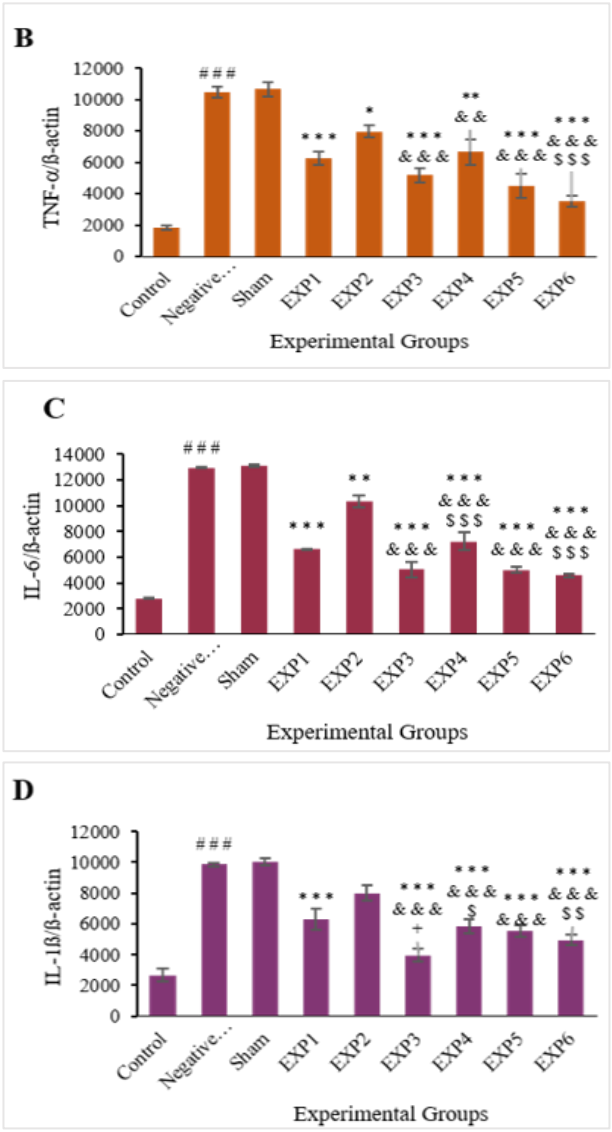

Figure 6. A) The representative Western blot analysis of TNF-α, IL-6, and IL-1ß. Comparison of B) TNF-α, C) IL-6, and D) IL-1ß expression levels. Statistical significance is denoted by the following symbols: the relationship between the negative control group and the control group is indicated by # (mean ± SEM; $p < 0.05$#, $p < 0.01$##, $p < 0.001$###); the relationship between the experimental groups and the negative control group is indicated by * (mean ± SEM; $p < 0.05$*, $p < 0.01$**, $p < 0.001$***); the relationship between experimental groups 3–6 and the sham group is indicated by & (mean ± SEM; $p < 0.05$&, $p < 0.01$&&, $p < 0.001$&&&); the relationship between experimental groups 3 and 5 and experimental group 1 is indicated by + (mean ± SEM; $p < 0.05$+, $p < 0.01$++, $p < 0.001$+++); and the relationship between experimental groups 4

and 6 and experimental group 2 is indicated by $ (mean ± SEM; $p < 0.05$, $p < 0.01$$, $p < 0.001$$$).

Histological Analysis

Histological results of subcutaneous tissue examination

Histological analysis of subcutaneous tissue from the abdominal region was conducted utilizing hematoxylin-eosin staining and examined under a light microscope and quantified using ImageJ.

The control group's subcutaneous tissue was entirely normal, free of inflammatory cells and fibrous tissue (Figure 7A). In the negative control group's subcutaneous tissue, the rate of fibroblast proliferation and fibrous tissue formation was 3.01 ± 0.213 which is significantly higher than control group (0.14 ± 0.113) ($p<0.0001$). In addition, subcutaneous nodule formation was also evident and collagen densification was moderate. Infiltration of inflammatory cells showed a significant increase compared to the control group (2.88 ± 0.227 vs 0.16 ± 0.018) (Figure 7B, J and K). Likely, in the sham group (subcutaneous injection of DMSO solvent in diabetic rats after 21 days of injection), fibroblast proliferation and fibrous tissue formation increased at the injection site by a mean of 3.57 ± 0.202 versus control ($p<0.0001$). Subcutaneous nodule formation was seen. Collagen densification was moderate, and blood vessels were moderate to high. Infiltration of inflammatory cells was remarkably increased (3.75 ± 0.164) compared to the control group (Figure 7C, J and K). In experimental group 1 (EXP1), fibroblast proliferation and moderate fibrosis were observed at the injection site by mean of 2.43 ± 0.211, which is significantly lower than negative control group ($p<0.05$). A moderate density of collagen was observed in terms of its status and blood vessels were moderate. The rate of inflammatory cell infiltration (1.75 ± 0.159) was statistically less than negative control ($p<0.01$) (Figure 7D). Histological analysis of experimental group 2 (EXP2) showed that the fibroblast proliferation and fibrous formation at the injection site had not significant difference with negative control by the mean of 2.84 ± 0.184 for EXP2 vs 3.01 ± 0.213 for negative control. Collagen deposition was denser than the negative control group. In contrast, infiltration of inflammatory cells by a mean of 2.13 ± 0.125 and $p<0.05$ was significantly less than negative control (Figure 7E, J and K). In experimental group 3 (EXP3), fibrosis with an average of 1.71 ± 0.210 showed a significantly decrease compared to negative control ($p<0.01$), but subcutaneous necrosis was observed with mild collagen deposition. Blood vessel density was moderate, and inflammatory cell infiltration significantly reduced compared to the negative control group (by a mean of 1.25 ± 0.170 and $p<0.001$). Tannic acid injection alongside regular insulin in EXP3 reduced amyloid deposits compared to the negative control, EXP1 (which received only regular insulin), and the sham group that was given DMSO solvent (Figure 7F, J and K). In experimental group 4 (EXP4), fibroblast proliferation and fibrous tissue formation showed significant decrease (2.42 ± 0.192) compared to negative control ($p<0.05$), but subcutaneous necrosis was observed with moderate to low collagen deposition and a low presence of blood vessels. The infiltration of inflammatory cells increased to 2.46 ± 0.161 which was not significantly different from the negative control group. (Figure 7G, J and K). In experimental group 5

(EXP5), fibroblast proliferation and fibrous tissue formation were statistically less than negative control (with an average of 0.29 ± 0.145 and p<0.0001), and subcutaneous nodules were not formed. Collagen was very loose and weak and almost devoid of vessels. No inflammatory cells were observed (Figure 7H, J and K). In experimental group 6 (EX6P), fibroblast proliferation and fibrous tissue formation were observed to a moderate to severe degree at the injection site which was similar to negative control (3.01 ± 0.213 and 3.28 ± 0.207), but infiltration of inflammatory cells showed a significant decrease by a mean of 2.34 ± 0.152 and p<0.05. There was mild necrosis with hyaline formation at the injection site. Subcutaneous nodule formation was evident. Collagen densification was more intense, and blood vessels were moderate to high (Figure 7I, J and K).

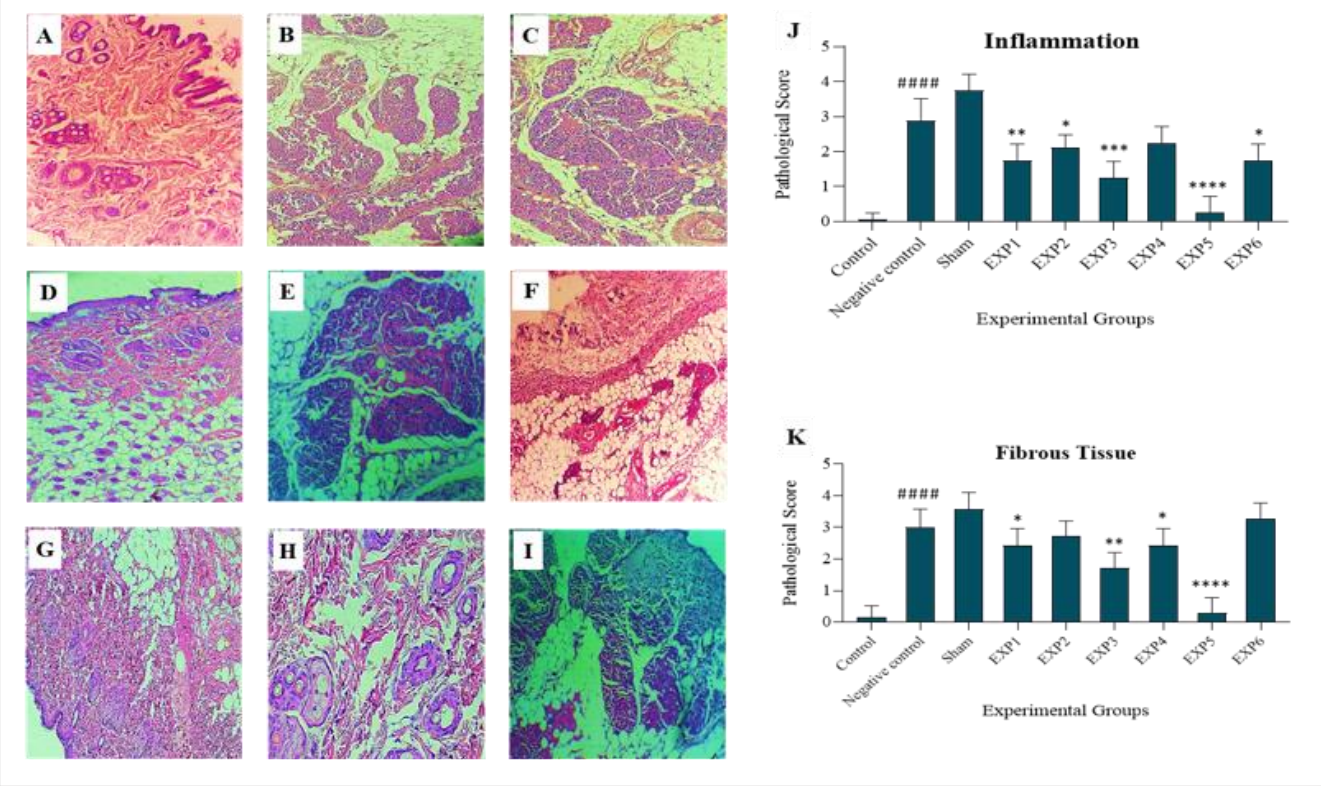

Figure 7. Histological examination of subcutaneous tissue A) Control group, B) Negative control group, C) Sham group, D) EXP1, E) EXP2, F) EXP3, G) EXP4, H) EXP5, I) EXP6 (hematoxylin-eosin staining, Magnification ×100). J) Quantified Inflammation in subcutaneous tissue, and K) Quantified Fibrous tissue in subcutaneous tissue. Statistical significance is denoted by the following symbols: the relationship between the negative control group and the control group is indicated by # (mean ± SEM; $p < 0.0001$####); the relationship between the experimental groups and the negative control group is indicated by * (mean ± SEM; $p < 0.05$*, $p < 0.01$**, $p < 0.001$***, $p < 0.001$****).

Histological results of pancreatic tissue examination

Hematoxylin and Eosin staining was used to examine the pancreatic inflammation and Islets tissue changes. In the control group, the acini and islets of Langerhans was normal without any pathological lesions (Figure 8A). In the negative control group, the majority of the islets of Langerhans were destroyed by an average of 3.70 ± 0.153 ($p<0.0001$) and infiltration of mononuclear inflammatory cells, predominantly lymphocytes, was significantly increased in intercellular spaces compared to control group (3.31 ± 0.166 and $p<0.0001$). Inflammatory cells entered the acini mildly, and inflammatory cells were also present in the adipose tissue around the pancreas (Figure 8B, J and K). In the sham group, hyperemia and mild edema were observed in the islets of Langerhans which led to significant decrease in the population of islet cells (1.83 ± 0.131) compared to the control group ($p<0.001$). No signs of inflammation were observed, but there was degeneration in the acini below 10% (Figure 8C, J and K). In experimental group 1 (EXP1), which became diabetic and received regular insulin subcutaneously for 21 days, the acini and islets of Langerhans showed a normal condition without significant pathological lesions compared to the control group, but the Islet degeneration (0.3 ± 0.104) and inflammatory cells infiltration (0.4 ± 0.166) was significantly less than negative control group ($p<0.0001$ for both parameters), (Figure 8D, J and K). In experimental group 2 (EXP2), the condition of the acini was normal, but the degeneration of the Langerhans islets cells was increased to 0.77 ± 0.134 which was significantly more than the healthy sample ($p<0.05$). Hyaline cysts were seen in the vascular wall. furthermore, there was no significant increase in inflammatory cells infiltration (Figure 8E, J and K). In experimental group 3 (EXP3), acini and Langerhans islets were normal without pathological lesions (0.31 ± 0.126) compared to the negative control ($p<0.0001$) and sham groups ($p<0.001$) (Figure 8F, J and K). In experimental group 4 (EXP4), hyperemia and mild edema were seen in the islets of Langerhans which was led to mild increased Islet cell degeneration by an average of 0.85 ± 0.153 compared to the control group ($p<0.05$). Furthermore, the infiltration of inflammatory cells was decreased to 0.32 ± 0.138 which is significantly less than the negative control ($p<0.0001$). Hyaline cysts were seen in some vessel's walls (Figure 8G, J and K). In experimental group 5 (EXP5), the acini were normal and the islets of Langerhans had relatively few destructive cells (by a mean of 0.21 ± 0.123) compared to the negative control ($p<0.0001$) and sham groups ($p<0.001$). They also lacked inflammatory cells (Figure 8H, J and K). In experimental group 6 (EXP6), hyperemia and mild edema were seen in the islets of Langerhans, but compared to the negative control and sham groups, they lacked inflammatory cells. In addition, destroyed islets of Langerhans were increased ($p<0.05$) compared to control group with an average of 0.73 ± 0.201. There was also less than 10% degeneration in the acini. The presence of inflammatory cells around the pancreas was negative (Figure 8I, J and K).

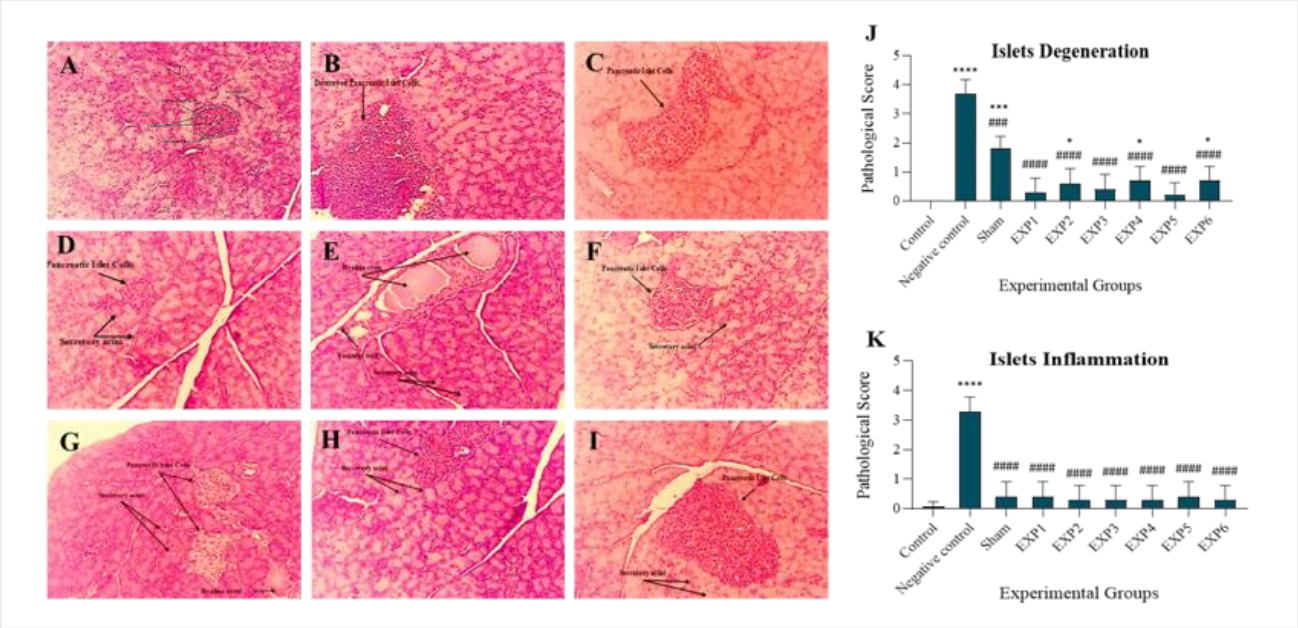

Figure 8. Histological examination of pancreatic tissue A) Control group, B) Negative control group, C) Sham group, D) EXP1, E) EXP2, F) EXP3, G) EXP4, H) EXP5, I) EXP6 (hematoxylin-eosin staining, Magnification ×100). J) Quantified islet degeneration in pancreatic tissue, and K) Quantified islet inflammation in pancreatic tissue. Statistical significance is denoted by the following symbols: the relationship between the negative control group and the control group is indicated by # (mean ± SEM; $p < 0.001$###; $p < 0.0001$####); the relationship between the experimental groups and the negative control group is indicated by * (mean ± SEM; $p < 0.05$*, $p < 0.01$**, $p < 0.001$***)

DISCUSSION

This study investigated the effects of tannic acid and Crocin on insulin-amyloid fibril-related metabolic and inflammatory alterations in male Wistar rats. In diabetic rats, both agents reduced serum glucose, cholesterol, and LDL levels while enhancing HDL levels. The most notable improvements were observed in experimental groups EXP3 and EXP5. Inflammatory cytokines, including TNF-α, IL-6, and IL-1ß, were significantly elevated in the negative control group, whereas the experimental groups demonstrated marked reductions. Tannic acid and Crocin presence lowered cytokine levels and ameliorated the inflammatory profile, suggesting their efficacy in mitigating amyloid-induced systemic inflammation.

Histopathological studies showed that Crocin and tannic acid decreased the tissue damage and fibrosis caused by amyloid accumulation. EXP3 and EXP5 exhibited reduced fibroblast proliferation, diminished inflammatory cell infiltration, and less fibrous tissue formation in comparison with the negative control group. Moreover, the histology of the pancreas provided further evidence for the preventive benefits of the compounds, as it showed reduced inflammation while preserving the islets of Langerhans in the experimental groups (Figure 9). Studies have demonstrated that tannic acid may exert anti-inflammatory and lipid-lowering effects through the modulation of pathways such as JAK/STAT and TGF-β, both critical in metabolic regulation [19]. In our study, a

significant increase in serum cholesterol levels was observed in the negative control group, whereas all experimental groups exhibited a reduction in cholesterol levels, with significant declines in EXP2, EXP4, and EXP6. Serum LDL levels were significantly lower in both experimental and sham groups, with notable reductions in EXP3 and EXP4. Compared to the negative control, both the experimental and sham groups showed increases in serum HDL levels. However, these levels were lower in EXP3 and EXP6 than those of the other experimental groups. The present findings indicate that dietary tannins and Crocin could reverse amyloid-induced dysmetabolic changes that affect the lipid profile. Marked reduction in the inflammatory cytokines, TNF-α, IL-6, and IL-1ß, were observed in the experimental groups compared with the negative control, signifying an anti-inflammation effect. Examination of histopathological findings suggests preservation of the pancreatic architecture, reduced amyloid deposition, and inflammatory cell infiltration in experimental groups, particularly EXP3 and EXP5.

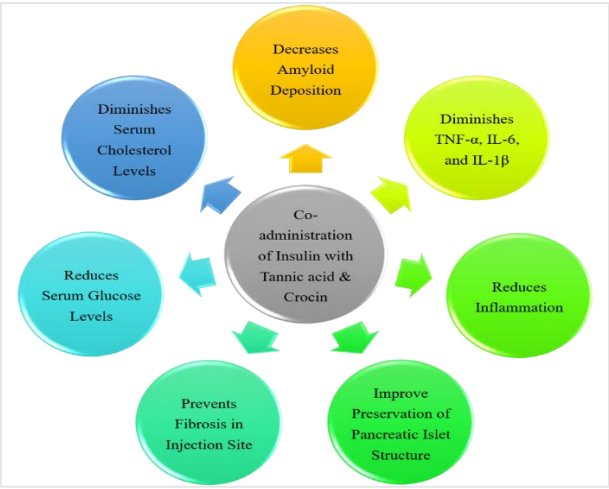

Figure 9. An overview of the study results obtained from the co-administration of Insulin with tannic acid and crocin.

Amyloid deposits, mainly in the pancreas, promote diabetes and other metabolic disorders. Accumulation of amyloid in the islets of Langerhans typically results in cell dysfunction, reduced insulin production, and ultimately, the destruction of these crucial cells. Reducing amyloid levels is crucial for pancreatic restoration, as it may preserve islet integrity, boost insulin production, and improve glucose metabolism [20]. Sequeira *et al.* found flavonoids can prevent IAPP aggregation, reduce amyloid deposition, and improve glycemic control in diabetic rats, suggesting they may act as medicinal agents [21]. Our study found that tannic acid and Crocin, both polyphenolic compounds, may have similar effects on amyloid aggregation and glycemic regulation, suggesting potential therapeutic applications. In the present study, the negative control showed significant destruction of islets of Langerhans, without notable infiltrative mononuclear inflammatory cells, primarily lymphocytes. The sham group showed a small degree of swelling and congestion in the islets, as well as a reduced number of islet cells, indicating that even very minor manipulations can be significant in pancreatic morphology, while interestingly, treatment with regular human insulin for experimental group 1 (EXP1) led to a condition near to normal in the acinar and islet regions of the pancreas. All experimental groups in which tannic acid and Crocin were present (EXP3-EXP6) displayed various degrees of hyperemia and edema but without significant inflammatory cell infiltration. This signifies that these compounds presence might be beneficial in ameliorating the inflammation and maintaining the architecture of the pancreas. We should mention here a

limitation of the study which is the lack of objective biochemical monitoring of potential alloxan-induced nephrotoxicity in diabetic rats: while we have monitored the animals for visible signs, biochemical measurements were not done in this regard. Chronic inflammation is diagnosed as the main problem in metabolic diseases such as diabetes, whereby the high levels of pro-inflammatory cytokines, TNF-α, IL-6, and IL-1β, are the main culprits in the damage inflicted on tissues and the consequent metabolic disarray [22]. Anti-inflammatory properties promoted by Crocin inhibiting NF-κB activation are considered to be a key modulator in pro-inflammatory cytokine expression. This outcome leads to lower levels of TNF-α, IL-6, and IL-1β. Tannic acid, on the other hand, helps mitigating inflammation because of its antioxidant activity and membrane-stabilizing effect by decreasing the activation of the above-named pro-inflammatory transcription factors. The integrity of pancreatic tissue may be preserved through active inflammation reduction and the decrease of harmful fibrils [23]. Our study showed that the levels of such cytokines substantially decreased in the serum with the presence Crocin and tannic acid in the experimental groups as compared to the negative control. These findings support the role of the studied natural compounds in alleviating inflammation and oxidative stress in diabetes. The histopathology of pancreas also depicted decreased infiltration of inflammatory cells and preserved pancreatic architecture in both groups that received treatment with either Crocin or tannic acid. The improved metabolic and inflammatory profile suggests, together with these findings, the therapeutic potential of such compounds in managing insulin-induced amyloidosis. A meta-analysis has revealed increased levels of pro-inflammatory cytokines like IL-6, TNF-α, and IL-1β in age-related diseases, suggesting a link between aging and systemic inflammation [24]. Higher IL-6 levels have also been observed in diabetic nephropathy patients, indicating a link between inflammation and kidney damage in diabetes [25]. Inflammatory markers such as TNF-α, IL-6, and IL-1β remain key targets for therapies in metabolic and autoimmune diseases; the upregulation of all these markers brings about chronic inflammation with the further progression of the disease, tissue damage, and metabolic derangement. Crocin and tannic acid are anti-inflammatory agents that may block these effects. Crocin inhibits TNF-α and IL-6 secretion by suppressing NF-κB activation, whereas tannic acid ameliorates antioxidant status and cytoprotection, inhibiting pro-inflammatory signaling. Taken together with the results from the histopathological studies showing protected pancreatic architecture along with reduced infiltration of inflammatory cells in the Crocin and tannic acid treatment experimental groups, these results strongly support their protective anti-inflammatory action. The Crocin -treatment group also showed significantly downregulated serum levels of glucose, cholesterol, and LDL, as well as upregulated HDL levels, thus minimizing amyloid-mediated tissue damage and fibrosis and thereby providing a protective influence on pancreatic islet integrity. These effects corroborate the findings in other studies in which Crocin was reported to increase insulin sensitivity, lower fasting blood glucose concentrations, and ameliorate diabetic-induced

injury in the pancreas in diabetic rat models [26]. Additionally, Crocin is said to inhibit selectively the aggregation of human islet amyloid polypeptide, an important pathologic event in type 2 diabetes [27]. "Remarkably, experimental groups EXP4 and EXP6, which received higher doses or a combination treatment, exhibited significantly lower TNF-α and IL-6 levels compared to treatment group EXP2, indicating a potential dose-dependent or synergistic effect."

These findings substantiate the therapeutic potentials of Crocin and tannic acid in suppressing inflammation and staving off tissue damage toward insulin-amyloid fibrils.

Ejiofor et al. showed that tannic acid administered orally at 200–400 mg/kg significantly reduced fasting blood glucose, reversed lipid profiles, and inhibited oxidative stress in high-fat and fructose diet-induced obesity in rats, preserving pancreatic and liver structure [28]. Tannic acid is a natural antioxidant with great therapeutic potential against metabolic and inflammatory disturbances [29]. this study showed a reduction of serum glucose, cholesterol, and LDL levels, with an increase in HDL levels in diabetic male Wistar rats. Tannic acid decreases inflammatory cytokines and reduces the inflammatory profile associated with amyloid-induced systemic inflammation. Both studies point toward the potency of tannic acid in improving metabolic outcomes and protection against tissue damage for the maintenance of organ integrity. Crocin and tannic acid can both scavenge free radicals, thereby reducing oxidative stress, modulating inflammatory pathways, and reducing levels of pro-inflammatory cytokines, which may be beneficial for diabetic patients [30]. As adjuncts, Crocin and tannic acid can work with metformin and insulin therapy to improve glycemic control and reduce amyloid-related complications. Since they are natural compounds, they can be developed as dietary supplements, which can be easily incorporated into a patient's daily regimen and improve adherence to treatment [31].

CONCLUSION

Insulin-derived amyloidosis is a problem for many diabetic patients, especially those on long-term insulin therapy with consequences such as impaired blood glucose control. Crocin and tannic acid are showed here to mitigate the effects of insulin amyloids The normalization of inflammatory cytokine levels, along with improved histological findings, indicates a synergistic mechanism where both compounds reduce oxidative stress, suppress inflammation, and protect pancreatic and renal tissues from further damage.

REFERENCES

[1] P. Garg and N. Duggal, "Type 2 diabetes mellitus, its impact on quality of life and how the disease can be managed-a review," *Obesity Medicine,* vol. 35, p. 100459, 2022.

[2] X. Lu, Q. Xie, X. Pan, R. Zhang, X. Zhang, G. Peng*, et al.*, "Type 2 diabetes mellitus in adults: pathogenesis, prevention and therapy," *Signal transduction and targeted therapy,* vol. 9, p. 262, 2024.

[3] R. Akter, P. Cao, H. Noor, Z. Ridgway, L.-H. Tu, H. Wang*, et al.*, "Islet amyloid polypeptide: structure, function, and pathophysiology," *Journal of diabetes research,* vol. 2016, p. 2798269, 2016.

[4] N. Verma, G. V. Velmurugan, E. Winford, H. Coburn, D. Kotiya, N. Leibold*, et al.*, "Aβ efflux impairment and inflammation linked to cerebrovascular accumulation of amyloid-forming amylin secreted from pancreas," *Communications biology,* vol. 6, p. 2, 2023.

[5] N. Verma and F. Despa, "The association between renal accumulation of pancreatic amyloid-forming amylin and renal hypoxia," *Frontiers in Endocrinology,* vol. 14, p. 1104662, 2023.

[6] S. Despa, S. Sharma, T. R. Harris, H. Dong, N. Li, N. Chiamvimonvat*, et al.*, "Cardioprotection by controlling hyperamylinemia in a “humanized” diabetic rat model," *Journal of the American Heart Association,* vol. 3, p. e001015, 2014.

[7] A. F. Raimundo, S. Ferreira, I. C. Martins, and R. Menezes, "Islet amyloid polypeptide: a partner in crime with Aβ in the pathology of alzheimer's disease," *Frontiers in molecular neuroscience,* vol. 13, p. 35, 2020.

[8] L. Karkhaneh, S. Hosseinkhani, H. Azami, Y. Karamlou, A. Sheidaei, E. Nasli-Esfahani*, et al.*, "Comprehensive investigation of insulin-induced amyloidosis lesions in patients with diabetes at clinical and histological levels: A systematic review," *Diabetes & Metabolic Syndrome: Clinical Research & Reviews,* vol. 18, p. 103083, 2024.

[9] A. Baldwin and B. W. Booth, "Biomedical applications of tannic acid," *Journal of Biomaterials Applications,* vol. 36, pp. 1503-1523, 2022.

[10] K Ono, K Hasegawa, H Naiki, M Yamada, "Anti-amyloidogenic activity of tannic acid and its activity to destabilize Alzheimer's beta-amyloid fibrils in vitro" *Biochimica Piophysica Acta*, vol 1690, pp.193-202, 2004.

[11] S. V. Jasemi, H. Khazaei, M. R. Morovati, T. Joshi, I. Y. Aneva, M. H. Farzaei*, et al.*, "Phytochemicals as treatment for allergic asthma: Therapeutic effects and mechanisms of action," *Phytomedicine,* vol. 122, p. 155149, 2024.

[12] A. Ghahghaei, S. Z. Bathaie, H. Kheirkhah, and E. Bahraminejad, "The protective effect of crocin on the amyloid fibril formation of Aβ42 peptide in vitro," *Cellular & molecular biology letters,* vol. 18, pp. 328-339, 2013.

[13] V. L. Bodiga, M. R. Kudle, P. K. Vemuri, and S. Bodiga, "Crocin inhibits urea-induced amyloid formation by bovine β-lactoglobulin," *New Journal of Chemistry,* vol. 45, pp. 2589-2596, 2021.

[14] T. Szkudelski, "The mechanism of alloxan and streptozotocin action in B cells of the rat pancreas," *Physiological research,* vol. 50, pp. 537-546, 2001.

[15] C. C. Allain, L. S. Poon, C. S. Chan, W. Richmond, and P. C. Fu, "Enzymatic determination of total serum cholesterol," *Clinical chemistry,* vol. 20, pp. 470-475, 1974.

[16] W. Richmond, "Preparation and properties of a cholesterol oxidase from Nocardia sp. and its application to the enzymatic assay of total cholesterol in serum," *Clinical chemistry,* vol. 19, pp. 1350-1356, 1973.

[17] M. F. Lopes-Virella, P. Stone, S. Ellis, and J. A. Colwell, "Cholesterol determination in high-density lipoproteins separated by three different methods," *Clinical chemistry,* vol. 23, pp. 882-884, 1977.

[18] W. T. Friedewald, R. I. Levy, and D. S. Fredrickson, "Estimation of the concentration of low-density lipoprotein cholesterol in plasma, without use of the preparative ultracentrifuge," *Clinical chemistry,* vol. 18, pp. 499-502, 1972.

[19] R. A. Youness, R. Kamel, N. A. Elkasabgy, P. Shao, and M. A. Farag, "Recent advances in tannic acid (gallotannin) anticancer activities and drug delivery systems for efficacy improvement; a comprehensive review," *Molecules,* vol. 26, p. 1486, 2021.

[20] A. Mukherjee, D. Morales-Scheihing, N. Salvadores, I. Moreno-Gonzalez, C. Gonzalez, K. Taylor-Presse*, et al.*, "Induction of IAPP amyloid deposition and associated diabetic abnormalities by a prion-like mechanism," *Journal of Experimental Medicine,* vol. 214, pp. 2591-2610, 2017.

[21] I. R. Sequeira and S. D. Poppitt, "Unfolding novel mechanisms of polyphenol flavonoids for better glycaemic control: Targeting pancreatic islet amyloid polypeptide (IAPP)," *Nutrients,* vol. 9, p. 788, 2017.

[22] B. M. Razavi and H. Hosseinzadeh, "Saffron: a promising natural medicine in the treatment of metabolic syndrome," *Journal of the Science of Food and Agriculture,* vol. 97, pp. 1679-1685, 2017.

[23] M. Badavi, S. A. Mard, M. Dianat, and N. Dashtbozorgi, "Crocin attenuates oxidative stress and inflammation in myocardial infarction induced by isoprenaline via PPARγ activation in diabetic rats," *Journal of Diabetes & Metabolic Disorders,* vol. 19, pp. 1517-1525, 2020.

[24] A. Tylutka, Ł. Walas, and A. Zembron-Lacny, "Level of IL-6, TNF, and IL-1β and age-related diseases: a systematic review and meta-analysis," *Frontiers in immunology,* vol. 15, p. 1330386, 2024.

[25] V. K. K. Reddy, G. Shiddapur, N. Jagdale, M. P. Kondapalli, S. Adapa, and G. Shiddapur, "Investigating Interleukin-6 levels in type 2 diabetes mellitus patients with and without diabetic nephropathy," *Cureus,* vol. 16, 2024.

[26] V. Behrouz, A. Dastkhosh, M. Hedayati, M. Sedaghat, M. Sharafkhah, and G. Sohrab, "The effect of crocin supplementation on glycemic control, insulin resistance and active AMPK levels in patients with type 2 diabetes: a pilot study," *Diabetology & metabolic syndrome,* vol. 12, p. 59, 2020.

[27] J. Lu, Z. Lu, L. Liu, X. Li, W. Yu, and X. Lu, "Identification of crocin as a new hIAPP amyloid inhibitor via a simple yet highly biospecific screening system," *Chemistry & Biodiversity,* vol. 18, p. e2100270, 2021.

[28] E. Ejiofor, E. Agwamba, C. Egedigwe-Ekeleme, P. Nweje-Anyalowu, H. Louis, I. Abalake*, et al.*, "Oral administration of tannic acid attenuates dyslipidemia, hyperglycemia, and oxidative stress in high-fat and fructose diet-induced obesity in rats," *Food Safety and Health,* vol. 3, pp. 250-263, 2025.

[29] Y. Wu, L. Zhong, Z. Yu, and J. Qi, "Anti-neuroinflammatory effects of tannic acid against lipopolysaccharide-induced BV2 microglial cells via inhibition of NF-κB activation," *Drug Development Research,* vol. 80, pp. 262-268, 2019.

[30] Z. Dhouafli, K. Cuanalo-Contreras, E. A. Hayouni, C. E. Mays, C. Soto, and I. Moreno-Gonzalez, "Inhibition of protein misfolding and aggregation by natural phenolic compounds," *Cellular and molecular life sciences,* vol. 75, pp. 3521-3538, 2018.

[31] P. Ansari, J. T. Khan, S. Chowdhury, A. D. Reberio, S. Kumar, V. Seidel*, et al.*, "Plant-based diets and phytochemicals in the management of diabetes mellitus and prevention of its complications: A review," *Nutrients,* vol. 16, p. 3709, 2024.